



Brazilian Journal of OTORHINOLARYNGOLOGY

www.bjorl.org



CASE REPORT

Pedunculated pleomorphic adenoma of uvula – a rare presentation[☆]



Sabarinath Vijayakumar ^a, Shilpa Divakaran ^{a,*}, Suhail Muzaffar ^b,
Mohammed Yusuf Mian ^a, Irfan Khan ^a

^a Sandwell and West Birmingham NHS Trust, Birmingham, United Kingdom

^b The Royal Wolverhampton NHS Trust, Wolverhampton, United Kingdom

Received 18 December 2020; accepted 19 December 2020

Available online 13 February 2021

Introduction

Pleomorphic adenomas account for only about 6.5% of tumors in minor salivary glands, despite being the most common (70%) of all salivary gland neoplasms.¹ The minor salivary glands neoplasms are relatively rare, with the palate as the most common site (66%), followed by buccal mucosa, lips and retromolar areas (1%).²

The uvula per se is a rare location for occurrence of such lesions, with only a few cases having been reported so far. The differential diagnosis includes squamous papilloma, other minor salivary gland tumors and epidermoid cyst, which commonly occurs in the pediatric age group.

Case report

A 43 year old male presented with a short duration history of sudden choking sensation while eating, followed by a foreign body sensation in the throat for 2 weeks. He saw a swelling at the back of his throat, which prompted him to come to

the hospital. He did not have any difficulty in breathing, although there was a slight discomfort while swallowing as well as snoring at night.

On examination, he was comfortable at rest, with no signs of respiratory distress. There was a roughly 2 cm globular smooth pedunculated mucosa-covered mass from the posterior aspect of the tip of uvula, with overlying prominent vessels (Fig. 1). The remainder of the head and neck examination was unremarkable.

A magnetic resonance imaging (MRI) scan showed an ovoid enhancing mass lesion with well-defined margins hanging from tip of the uvula, measuring 2.3 × 2.1 × 2 cm (LS × TS × AP), without any invasion of surrounding tissues (Fig. 2).

Excision was performed under general anesthesia. In head extension with a mouth gag, using bipolar diathermy, the pedunculated mass was identified attached to posterior aspect of entire length of uvula and adjoining soft palate on the right side. Incision was created along the attachment and the mass excised in toto along with a part of uvula and soft palate; a palatoplasty was done to create a neo-uvula.

On gross examination the tissue appeared to be a firm cream-colored intact rounded tissue fragment measuring 20 × 20 × 20 mm with attached light brown mucosa measuring 15 × 10 mm. Slicing revealed a firm, mucoid, cream colored cut surface (Fig. 3).

[☆] Peer Review under the responsibility of Associação Brasileira de Otorrinolaringologia e Cirurgia Cérvico-Facial.

* Corresponding author.

E-mail: shilpa.divakaran@nhs.net (S. Divakaran).

<https://doi.org/10.1016/j.bjorl.2020.12.013>

1808-8694/© 2021 Associação Brasileira de Otorrinolaringologia e Cirurgia Cérvico-Facial. Published by Elsevier Editora Ltda. This is an open access article under the CC BY license (<http://creativecommons.org/licenses/by/4.0/>).

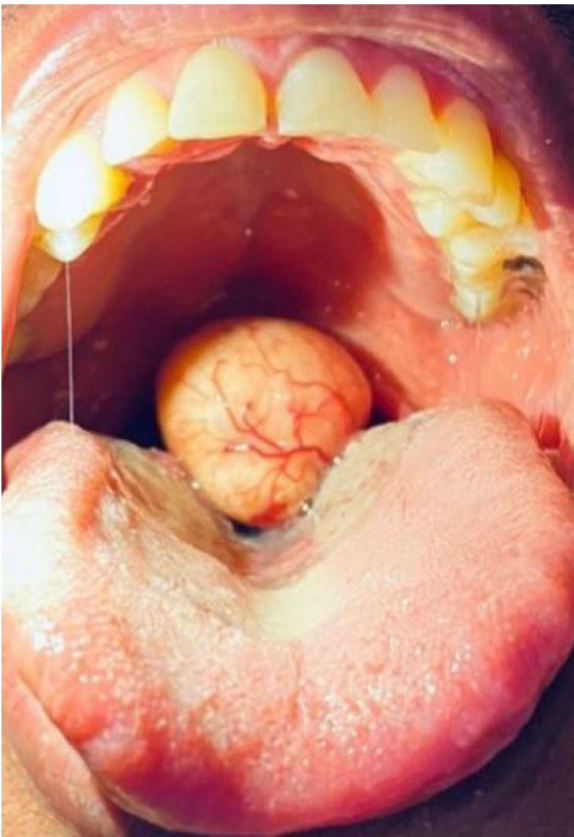


Figure 1 Intraoral appearance of the tumor.

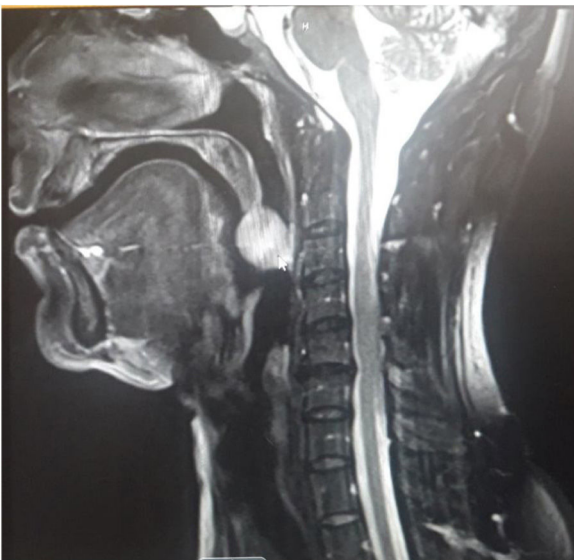

Figure 2 MRI showing ovoid enhancing mass lesion with well-defined margins hanging from tip of the uvula.

Microscopic examination of the lesion showed normal squamous mucosal lining epithelium containing minor salivary gland tissue which covered the entire surface of the lesion. A clear resection margin was present. The lesion was comprised of a well circumscribed benign mixed tumor composed of epithelial cells in sheets and cords embedded within a variably fibromyxoid stroma containing occasional

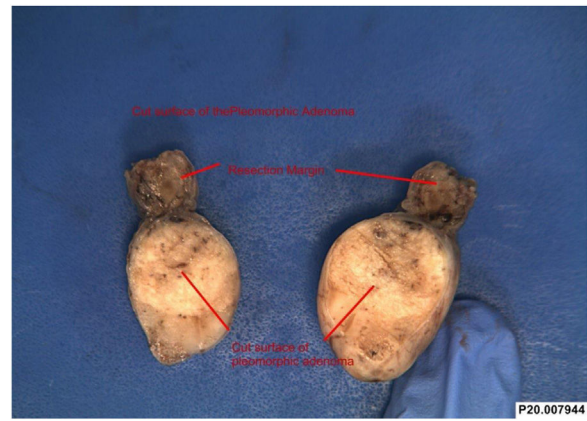


Figure 3 Excised tumor from the uvula.

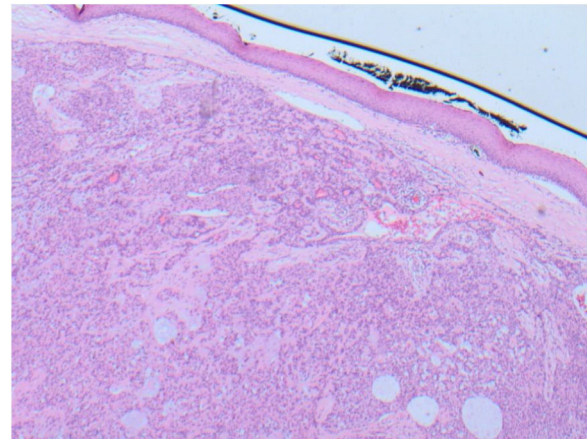


Figure 4 Histopathology of the excised lump showing a predominantly epithelial component arranged in tubules and cystic areas with myxomatous background, with palatal squamous epithelium above the lesion.

myoepithelial cells. The epithelial cells were essentially monomorphic with plasmacytoid appearance. There was no evidence of nuclear atypia, mitoses, perineural or vascular invasion. These morphological features were those of a benign pleomorphic adenoma (benign mixed tumor). There was normal salivary gland tissue noted at the resection margin of the pedunculated lesion and therefore the lesion was considered completely excised (Fig. 4).

The patient was followed up and after one month, the palatal scar had healed well on examination. At three months and six months after the procedure, the patient was doing well, without any changes in speech, velo-pharyngeal insufficiency or tumor recurrence.

Discussion

The most common benign tumor of the oral cavity is pleomorphic adenoma (50%), with the palate as the most common site. These tumors are seen between the fourth to sixth decade with a slightly female preponderance.^{3,4} Histologically, these tumors have a mixed appearance of myoepithelial and epithelial components in a background of variable fibromyxoid stroma with a pseudocapsule.⁵

Pleomorphic adenomas are slow growing tumors, with patients presenting with long-standing symptoms over several months: dysphagia, sleep disturbances and snoring. There was one case reported by Fidan et al.⁶ of uvular pleomorphic adenoma presenting with otalgia, however that patient also had changes in voice. In this case we had a male patient with a short history of foreign body sensation for only 2 weeks.

Pleomorphic adenomas arising in the uvula are quite rare, with few cases reported to date.⁶⁻⁸ The differential diagnosis include squamous papilloma and epidermal cyst (which occurs mostly in the pediatric age group). In this case, the appearance was that of a smooth mucosa-covered firm swelling, which is unlike that of a papilloma or epidermoid cyst.

MRI scan is the investigation of choice in evaluating such soft tissue lesions as they provide good demarcation. Pleomorphic adenomas have low T1 – weighted signal and high T2 – weighted signal on MRI.⁹

Surgical excision is the preferred method of treatment. Pleomorphic adenomas, if incompletely excised, can result in recurrence.¹⁰ In this case, a cuff of normal tissue was also taken keeping in mind the probability of a salivary gland tumour. The remaining uvula was reconstructed to avoid speech and swallowing problems.

Conclusion

Uvular lesions by themselves are quite uncommon. A possibility of minor salivary gland tumor should be kept in mind while encountering firm lesions of this area. Left untreated, these lesions can not only enlarge to cause significant morbidity in terms of airway and swallowing, but also carry a risk of malignant transformation.

Ethical approval

Consent taken from the Institute and patient for publishing clinical photographs and writing the case report.

Conflicts of interest

The authors declare no conflicts of interest.

References

1. Zhan KY, Khaja SF, Flack AB, Day TA. Benign parotid tumors. *Otolaryngol Clin North Am.* 2016;49:327–42.
2. Sentani K, Ogawa I, Ozasa K, Sadakane A, Utada M, Tsuya T, et al. Characteristics of 5015 salivary gland neoplasms registered in the Hiroshima tumor tissue registry over a period of 39 years. *J Clin Med.* 2019;8:566.
3. Buchner A, Merrell PW, Carpenter WM. Relative frequency of intra-oral minor salivary gland tumors: a study of 380 cases from northern California and comparison to reports from other parts of the world. *J Oral Pathol Med.* 2007;36:207–14.
4. Waldron CA, el-Mofty SK, Gnepp DR. Tumors of the intraoral minor salivary glands: a demographic and histologic study of 426 cases. *Oral Surg Oral Med Oral Pathol.* 1988;66:323–33.
5. Stennert E, Guntinas-Lichius O, Klussmann JP, Arnold G. Histopathology of pleomorphic adenoma in the parotid gland: a prospective unselected series of 100 cases. *Laryngoscope.* 2001;111:2195–200.
6. Fidan V, Yoruk O, Sutbeyaz Y. Otolgia due to the pleomorphic adenoma of uvula. *J Craniofac Surg.* 2009;20:571–3.
7. Motomura H, Harada T, Muraoka M, Taniguchi T. Elongated uvula with a pleomorphic adenoma: a rare cause of obstructive sleep apnea syndrome. *Ann Plast Surg.* 2000;45:61–3.
8. Li J, Guo L, Wang K. Large Mixed Tumors of salivary: two cases reports. *Lin Chung Er Bi Yan Hou Tou Jing Wai Ke Za Zhi.* 2014;28:1714–5.
9. von Stempel C, Morley S, Beale T, Otero S. Imaging of palatal lumps. *Clin Radiol.* 2017;72:97–107.
10. Ethunandan M, Witton R, Hoffman G, Spedding A, Brennan PA. Atypical features in pleomorphic adenoma—a clinicopathologic study and implications for management. *Int J Oral Maxillofac Surg.* 2006;35:608–12.